

cent. The blood urea was 46 mg. per 100 c.cm. There were no clinical symptoms of renal inadequacy, no thirst or headache, and the tongue was fairly clean. The patient, though thin, was in fair condition, and had been at work till shortly before admission.

On November 8th, the left kidney being judged the better of the two, nephrolithotomy was done on that side through an oblique lumbar incision, and masses of branched phosphatic calculi were removed through a cortical incision in the kidney through pouched and thinned-out tissue, opening into the calyces which contained the calculi; 5½ drachms were thus removed, and the renal area drained. The upper third of the kidney was that chiefly involved, and the remainder showed sound secreting tissue. The patient made an uneventful recovery from this operation, and left hospital feeling well on December 11th.

He returned to his home in Bloemfontein, and was re-admitted to hospital on January 11th, 1924, for operation on the right side. The left lumbar wound had healed well. On this occasion the urine from the bladder showed 1.2 per cent. urea—a marked improvement upon the previous occasion; the left kidney urea was 1.1 per cent., the blood urea was, as before, 46 mg. per 100 c.cm. Cultivations from the left kidney showed no organisms; there was a scanty growth of a streptococcus from the bladder urine. Indigo-carmin appeared from the left in thirty minutes with a free urinary secretion. From the right side there was a rapid arrhythmic secretion of a purulent urine, indigo-carmin appearing in fifty minutes.

On January 28th a right lumbar oblique incision was made, and a much sacculated kidney was exposed, the sacculation being mainly in the upper pole. Masses of phosphatic calculi, weighing 11 drachms 50 grains, were removed through a cortical incision in the thinned-out upper pole pouch. This left a big flabby upper sac leading to the calyces which had contained the calculi. As the walls of this sac showed no evidence of secreting tissue, and as it seemed only too probable this portion of the kidney would never heal, and only leave a persistent fistula, the sac was completely resected longitudinally, some deep mattress sutures of catgut being used for haemostasis, and the edges then approximated as accurately as possible, but room for drainage being allowed for. The kidney area was drained, the tube passing down to, but not into, the renal substance. The tube was removed in forty-eight hours and replaced by a small gauze drain. Hardly any leakage occurred.

Except for an attack of malaria and dysentery, from which the patient had previously suffered in East Africa, no untoward event marred his recovery. On March 1st the patient walked a distance of a mile to report himself; he had then no urinary symptoms, and the urine contained only a very small amount of pus, and under hexamine and acid sodium phosphate was acid in reaction.

The case can be taken to be definitely an ascending urinary infection from the original cervical injury, with resultant formation of calculi on both sides. There is no positive evidence to show exactly when calculi were first formed, but as a medical board, held in 1917 in England, stated that the patient had bilharzia, one can assume he then had haematuria, though there was no evidence adduced to prove that he had bilharzia—that is, there was no statement that ova had been found. It seems rather to have been assumed because the patient came from South Africa.

The resection of the upper pole of the right kidney proved quite successful, and is well worthy of adoption in cases of similar type. The chances of recurrence of calculi are considerable, but there is reason to hope that this may be prevented by keeping the urine acid by means of drugs and diet.

FIBROSIS OF THE LUNGS DUE TO THE INHALATION OF ASBESTOS DUST.

BY

W. E. COOKE, M.D., F.R.C.P.ED., D.P.H.,
PATHOLOGIST, WIGAN INFIRMARY.

(With Special Plate.)

THE following case is of importance because it is the first in English medical literature to be definitely proved.

Medical men in areas where asbestos is manufactured have long suspected the dust to be the cause of chronic bronchitis and fibrosis, and Professor J. M. Beattie has shown that the dust causes fibrosis in guinea-pigs. Asbestos contains, amongst other compounds, calcium and magnesium

silicates, and 40 per cent. of SiO₂, silica. The mineral fibre is quite translucent except at the fractured ends, where some change takes place, the fibre becoming blackened and fragmented. Asbestos dust, no matter from what part of the process it is collected, contains these blackened particles in large amounts (see photo-micrograph).

A woman, aged 33 years, had worked in asbestos factories since the age of 13, but for five years previous to her finally ceasing work in July, 1922, her attendances at the factory had been intermittent. She died on March 15th, 1924. Mr. E. N. Molesworth, coroner for Rochdale, at the suggestion of Dr. Mackichan, who performed the necropsy, sent the lungs for further examination.

An x-ray plate showed extensive fibrosis, more marked in the right lung, two calcareous glands at the root of the left lung, and two small calcareous particles in the base of the left lower lobe.

Macroscopical Appearances.

Right Lung.—The pleura is thickened over the entire surface of the lung, and shows the remains of dense adhesions to the chest wall and pericardium. The lung is firm and small. The glands at the root of the lung are larger than normal, and on section are black, show a thickened capsule, and some calcareous particles. On section, the lung is seen to be fibrosed and to a large extent airless, the lung tissue being replaced by fibrous tissue. In the apex there is a large cavity, the size of a peeled Tangerine orange. The middle and lower lobes show numerous small areas—varying in size from a hazel-nut to a pin's head—of caseation, some of which have proceeded to cavitation. The bronchi are dilated.

Left Lung.—The pleura is thickened and shows the remains of adhesions to the chest wall. The thickening and adhesions are not so marked as in the right lung. The lung is firmer than normal. At the root of the lung are two large calcareous masses, one the size of a large hazel-nut, the other about half that size—calcified tuberculous glands. The other glands are black, and show a thickened capsule. On section, the lung tissue cuts with greater resistance than normal. In the left apex there is an area of old scar tissue about the size of a sixpenny piece and a cavity the size of a walnut. Scattered throughout the lung are small areas of denser consistence than the rest of the lung, some of which show definite calcareous particles, others small areas of caseation. There is a considerable increase in the fibrous tissue.

Microscopical Appearances.

The right lung shows extensive fibrosis, caseous foci, and cavities with thick fibrous walls. Giant cells are numerous around the caseous areas, and tubercle bacilli are present.

The left lung shows the same condition, but the fibrosis is not so extensive.

In sections of both lungs, in the caseous areas, and in the fibrotic parts, are seen particles of mineral matter. These are of various shapes, but the large majority have sharp angles. The size varies from 393.6 to 3 microns in length. The photo-micrograph illustrates the sizes and shapes. The lymphatic glands show periadenitis and fibrosis.

The bronchi are dilated, the lining epithelium has disappeared, and there is extensive peribronchial fibrosis.

Memoranda :

MEDICAL, SURGICAL, OBSTETRICAL.

LYMPHOSARCOMA OF THE TONSIL REMOVED BY SLUDER'S GUILLOTINE ENUCLEATION.

LYMPHOSARCOMA of the tonsil grows so rapidly, and when removed so commonly returns, or gives rise to multiple leukaemic tumours, that I wish to report one case where removal has so far been followed neither by local recurrence nor by remoter metastatic disaster, though twenty months have passed since the operation.

In October, 1922, I was asked to see a lady, aged 72, who was able to swallow fluids only, and complained of pain in the throat, shooting to the left ear, severe enough to prevent sleep. The left tonsil was enlarged and almost touched the opposite side of the fauces. It was very hard and smooth, and was covered with a net of tortuous veins, which contrasted vividly with the almost ivory pallor of the underlying growth. At the upper pole of the tumour there was a ragged, crater-shaped, exquisitely sensitive ulcer the size of a threepenny piece. The tumour was very movable and no glands could be felt.

She told me that in 1877, when 27 years of age, a sharp fragment of mutton bone became fixed in her left tonsil, causing much pain, swelling, and inflammation. Various practitioners attempted its removal, but at the end of several weeks it came away without

WAGGETT AND FYFFE: TOOTH-PLATE REMOVED FROM RIGHT BRONCHUS.

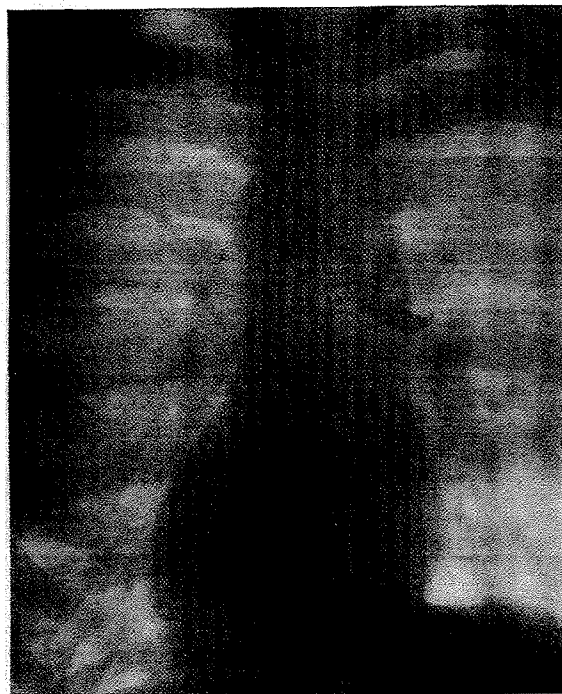


FIG. 1.

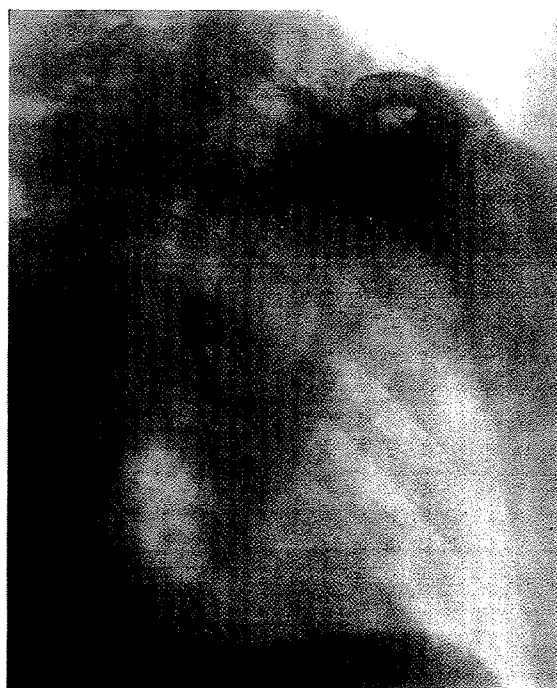

FIG. 2.

W. E. COOKE: FIBROSIS OF LUNGS DUE TO INHALATION OF ASBESTOS DUST.

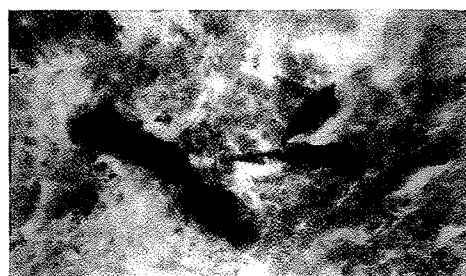


FIG. 1.—Section of lung showing asbestos particles. $\times 310$.

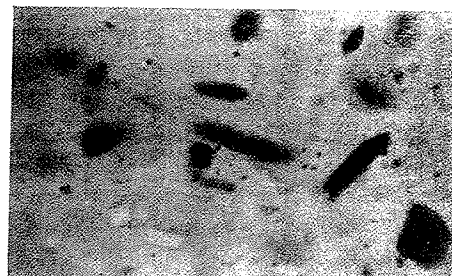


FIG. 2.—Asbestos dust. $\times 310$.

H. TEMPLE MURSELL: AN UNUSUAL CASE OF BILATERAL RENAL CALCULUS.

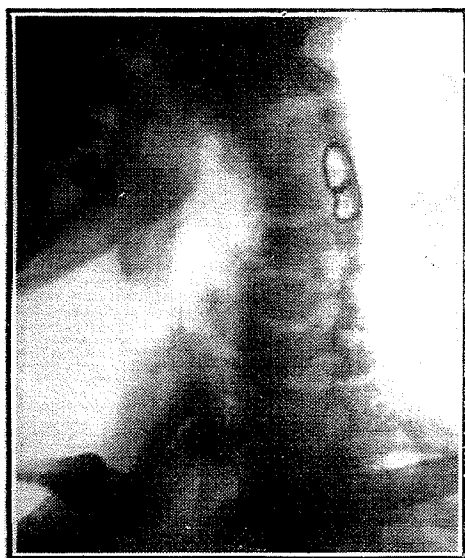

FIG. 1.—Silver wire through spinous processes of third and fourth cervical vertebrae. Superior articular processes of fourth cervical removed. 1915.

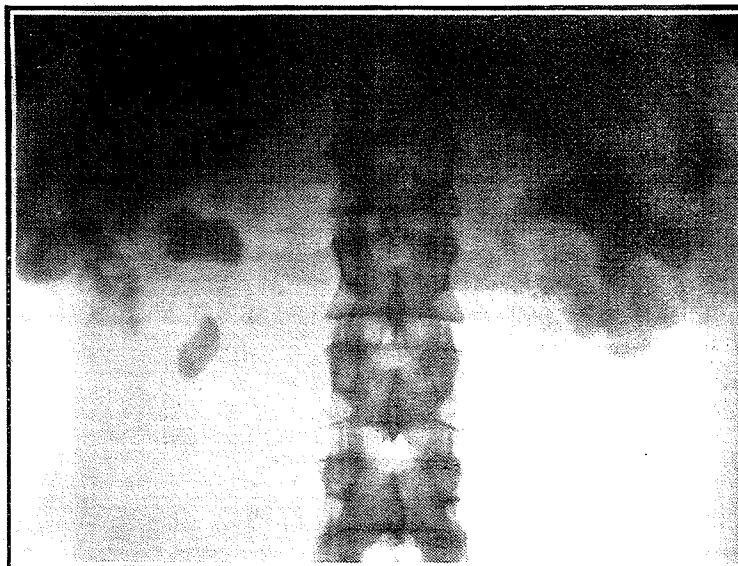


FIG. 2.—Bilateral renal calculi. 1923.